

# Staged Stem Cell-enriched Tissue (SET) Injections for Soft Tissue Augmentation in Hostile Recipient Areas: A Preliminary Report

Tunc Tiryaki · Necati Findikli · Demir Tiryaki

Received: 25 October 2010 / Accepted: 18 March 2011  
© Springer Science+Business Media, LLC and International Society of Aesthetic Plastic Surgery 2011

## Abstract

**Background** Autologous fat transplantation is frequently used for a variety of cosmetic treatments and difficult reconstructive indications such as involutinal disorders, hemifacial atrophy, sequelae of radiation therapy, or similar problems. However, the limitations of fat transplantation are well known in such difficult cases, particularly the long-term unpredictability of volume maintenance. The ideal method of preparing autologous fat grafts optimizes tissue survival and reduces the variability of outcomes. We propose that enriching traditionally prepared fat grafts with adipose-derived regenerative cells (ADRCs) represents one such method.

**Methods** Using a staged approach, we performed cell-enriched fat transfer by injecting autologous ADRCs into soft tissue that was recently grafted using traditional methods of fat transfer. Over a 3-year period, data were prospectively collected from 29 patients who underwent a single session of stem cell-enriched tissue injections (SET).

**Results** Cell-enriched grafts ranged in volume from 10 to 390 cc per recipient area and were obtained by manual or automated processes. The mean follow-up period was 10 months. Postoperative atrophy of the injected tissue was

minimal and subjectively did not change after 8 weeks. Of note, historically reported rates of atrophy range from 20 to 80%. All patients were satisfied with the primary result with no need for a secondary session except for the cosmetic cases.

**Conclusion** These preliminary results suggest that SET is safe and may provide superior results compared to traditional fat grafting. By performing the procedure in a staged approach, operating room expenses are minimized, which ultimately decreases the cost of the procedure. Adipose-derived regenerative cells may mitigate early ischemia by increasing angiogenesis, decreasing apoptosis, and modulating the local inflammatory response. This technique may be of particular value to the surgeon when grafting high volumes of fat or when faced with hostile recipient area conditions, including fibrosis and post radiation.

**Keywords** Stem cells · Plastic surgery · SET · Hostile recipient area · Lipoinjection · Tissue engineering · Fat transplantation · Adipose-derived stem cells

## Introduction

There is little debate about the fact that tissue engineering is one of emerging stars in many different fields of twenty-first century medicine. For plastic surgeons, two important questions should be addressed. The first is whether there is significant use for these new techniques in aesthetic and/or reconstructive surgery, and the second is whether plastic surgeons will play a large role in the field of regenerative medicine. Because of two recent revolutions, namely, the recognition of fat tissue as the most important source of stem cells in the human body and the relatively simple technique of isolating these cells from fat, plastic surgeons

---

T. Tiryaki (✉)  
Cellest Plastic Surgery Clinic, Altzeren sk. No: 5, Levent,  
Istanbul, Turkey  
e-mail: drtunctiryaki@gmail.com

N. Findikli  
Department of Tissue Engineering, Yildiz Technical University,  
Istanbul, Turkey

D. Tiryaki  
Department of Biophysics, Yenyuzuyil University, Istanbul,  
Turkey

might emerge as the specific group who can harvest stem cells in abundance and provide the other specialties with this never-ending regenerative power. Indeed, it is within our reach today to harvest as many mesenchymal stem cells as needed at the bedside for use back in the same patient after an isolation process of about 2 h. Our quest now is to determine whether this new technology is providing us with any advantage compared to our traditional treatment modalities.

Autologous fat transplantation is an ideal treatment for facial rejuvenation and soft tissue augmentation as it provides “like for like” tissue material, results in no incisional scar, and avoids complications associated with foreign materials. In fact, successful use of fat transplantation for various soft tissue defects as well facial volume replacement and rejuvenation has been widely described in the literature [1–3]. However, significant limitations to traditional fat transplantation remain, such as unpredictability and a variable rate of graft survival [4, 5]. Graft loss is likely due in part to necrosis, especially in injection areas where the circulation and wound-healing capacity is impaired by previous fibrosis due to surgery, injections, radiotherapy, or any other acquired pathology [6, 7]. Many steps to overcome these problems have been reported, including meticulous harvesting and injection techniques such as lipostructuring and lipolayering [8].

The limitations of traditional fat transplantation have led us to a recent innovation, the enrichment of the fat graft with adipose-derived regenerative cells (ADRCs). These autologous mesenchymal stem cells harvested from the fat have been shown to enhance angiogenesis, decrease adipose cell apoptosis, and modulate the local inflammatory response [9]. By combining traditional fat grafting with ADRCs, tissue viability and therefore the consistency of graft survival may be improved. To test this hypothesis, we used a novel strategy known as stem cell-enriched tissue (SET) injection [6, 9]. In SET injections, isolated autologous ADRCs are injected into an area of the patient’s body that received traditional fat grafts earlier that day. Adipose-derived regenerative cells are used to promote angiogenesis during the critical time of tissue engraftment, thus improving the survival rate of tissue and reducing post-operative volume loss.

In this case series, the regenerative cell suspension was prepared by two different methods depending on the volume of tissue needed. For transfers of less than 100 cc of enriched tissue, a manual cellular aphaeresis system was used. For fat transfers of more than 100 cc, we used the automated Celution System™ (Cytori Therapeutics; San Diego, CA), which isolated the ADRCs in a closed, optimized, and automated process. The device was able to digest up to 360 cc of lipoaspirate in a single process of approximately 120 min, which resulted in 5 cc of a

concentrated regenerative cell suspension. This report describes the preliminary results for SET injections into challenging graft recipient areas, including patients who had previously undergone unsuccessful traditional fat transfer attempts. To the best of our knowledge, this is the first report on the clinical use of ADRC-rich tissue transfers in patients with hostile graft recipient areas.

## Materials and Methods

We present 29 cases of SET injections in which either a large volume of fat was transferred or recipient bed circumstances were suboptimal due to various reasons. These cases included three lumpectomy reconstructions, 12 cosmetic breast augmentations, ten reconstructions of traumatic/iatrogenic soft tissue deficiencies, one Parry Romberg reconstruction, one pectus excavatus reconstruction, one reconstruction of polio-induced soft tissue deficiency, and one reconstruction of facial dermatofibromatosis sequel (Table 1). Informed consent was obtained from all the patients. Our protocol conformed to the guidelines of the 1975 Declaration of Helsinki and was approved by individual institutional review boards.

### Surgical Technique

The operations were performed under local anesthesia with or without sedation, and the grafts were harvested primarily from the lateral thighs, lower back, and abdomen. At the beginning of the procedure, the donor site was infiltrated with a solution of saline and diluted epinephrine (0.001%). For the aspiration and fat transfer, a 3-mm cannula and traditional Coleman injection cannulas were used, respectively. For cases in which less than 100 cc of SET was required, the graft was processed manually. In these instances, half of the lipoaspirate was transferred to the Laminar Flow Cell Isolation Corner in the operating room within 10 min of harvest in order to minimize cell death. In cases in which more than 100 cc of SET was required, half of the lipoaspirate was introduced into the Celution System within 10 min of harvest for cell isolation to begin.

While cell isolation was taking place, the majority of the fat transfer and tissue shaping was done using traditional lipostructuring techniques. For the injection, 1-cc syringes for the face and 5-cc syringes for the body were used in order to accurately control the volume of graft injected. To reduce the time of the procedure, two syringes were used simultaneously. While the one syringe was being used for an injection, the other was being filled with the graft material in preparation for the next injection. After the microfat grafting procedure was finished, the patient was sent to the ward to await ADRC injection, which in turn

**Table 1** Summary of case series

Indication	No. of procedures	SET volume (cc)	Method of isolation
Breast reconstruction, unilateral breast injection	3	120–280	Automated
Breast augmentation, bilateral breast injections	12	210–410	Automated
Acne sequels, facial region	2	5, 25	Manual
Liposuction sequel, unilateral thigh areas	2	52, 150	Manual
Soft tissue defect in the pubis area and labia major	1	63	Manual
Scarring in the chin area	1	28	Manual
Burn scar, right posterior and lateral lower limb	1	200	Automated
Unilateral replacement of breast implants with SET	1	285	Automated
Bilateral replacement of the breast implants with SET	1	670	Automated
Iatrogenic gluteal soft tissue sequel	1	68	Manual
Parry Romberg disease, unilateral facial area	1	42	Manual
Pectus excavatus, sternal area	1	120	Manual
Polio infection sequel, unilateral shoulder region	1	180	Manual
Dermatofibromatosis, frontal and zygomatic areas	1	46	Manual

reduced the operation theater occupation by as much as 120 min.

#### Manual Cell Isolation

If less than 100 cc of cell-enriched tissue was needed, we used an antibody-based cellular aphaeresis system. For each 20 cc of grafted fat, 20 mg of lipoaspirate was taken as a cellular source. Immediately after harvest, the lipoaspirate was taken to the laboratory where it was poured into 25- or 75-cm<sup>2</sup> tissue culture flasks and mixed with an enzyme cocktail for tissue digestion. The enzyme cocktail consisted of type II collagenase (Invitrogen, Carlsbad, CA) and trypsin (Invitrogen). The mixture was then placed in a water bath and incubated at 37°C with continuous and rigorous shaking. After the incubation period of 40–60 min, the mixture was left to settle and the stromal vascular fraction (SVF) was filtered through 100- and 40- $\mu$ m filters in order to remove tissue debris and extracellular material. After filtration, the solution was mixed with equal amounts of stop solution, which contained DMEM (Invitrogen), L-glutamine (Invitrogen), antibiotics cocktail containing penicillin and streptomycin (Invitrogen), and 10% of the patient's own serum to inactivate the enzyme action. The cell suspension was then centrifuged at 1300 rpm for 10 min. The pellet was re-suspended with red blood cell lysis solution and consequently centrifuged again in preparation for magnetic separation.

#### Manual Cell Separation

For cell separation, the QuadroMACS system (Miltenyi Biotech, Bergisch Gladbach, Germany) was used. Pelleted cells were re-suspended with rinsing solution (Miltenyi

Biotech) which contained 0.2% HSA. In order to separate mature blood cells from cells with stem cell potential, a lineage cell depletion kit (Miltenyi Biotech) with LS separation columns (Miltenyi Biotech) was used according to the manufacturer's instructions. At the final step, the concentrated stem-cell-rich cell population was re-suspended in 2–5 cc of the patient's own platelet-rich plasma (PRP) and immediately prepared for injection. Together with the isolation step, this process took approximately 120 min.

#### Automated Preparation of SET

In cases in which more than 100 cc of enriched tissue was needed, we used the automated Celution System<sup>TM</sup> (Cytori Therapeutics; San Diego, CA) which uses a similar isolation process without a magnetic unit, in a closed system with a proprietary good manufacturing practice (GMP)-standard, clinical-grade enzyme. The device has been optimized and standardized for the extraction of ADRCs from adipose tissue. The device can process 120–360 cc of adipose tissue and generates a 5-cc cell suspension which is then mixed with 2–5 cc of the patient's own PRP before injection. This process took 90–120 min, depending on the volume of adipose processed.

#### SET Injection

The readily prepared autologous ADRC/PRP solution was injected with a 30-G needle directly into the fat grafted area, using the fat graft as a living transfer scaffold. Effort was made to distribute the ADRC/PRP solution evenly throughout the grafted area. The time of ADRC/PRP injection ranged from 20 to 60 min.

## Results

In cases with manual cell isolation, a mean of  $25.9 \pm 7.4$  ml of fat tissue was processed for enzymatic cell separation, resulting in  $(19.1 \pm 6.2) \times 10^6$  mononuclear cells per case. Of them, 30–50% of the cells with mature hematopoietic surface antigens such as T cells, B cells, NK cells, dendritic cells, monocytes, granulocytes, erythroid cells, and their committed precursors were discarded by magnetic separation using a lineage depletion kit. The residual cell population that was rich in ADRCs was passed through the column and then concentrated/homogenized in the patient's own serum before use.

We performed cell-enriched autologous fat grafting by combining ADRCs with traditional liposuction techniques. Over a 3-year period we collected data from 29 patients who underwent a single session of SET. The only complication was subcutaneous ecchymosis in a few cases, all of which resolved spontaneously in 1–2 weeks.

In the cases presented in this report, SET ranged in volume from 10 to 390 cc per recipient area and was obtained by manual aphaeresis or the automated Celution System (Table 1). All patients were followed with serial physical examination and photography at 4, 8, and 12 weeks, then 6 and 12 months. At this writing, 19 of the 29 patients have been followed for more than 12 months, with a maximum follow-up period of 36 months. In all patients, the author's subjective assessment of postoperative atrophy of the injected tissue was minimal and did not change after 8 weeks. In particular cases, we were able to observe not only better graft uptake, but also a subjective gradual rejuvenation of the skin overlying the graft area. The only patients requesting a secondary procedure were three breast augmentation patients and one reconstructive breast case; they wanted to further improve the outcome.

## Discussion

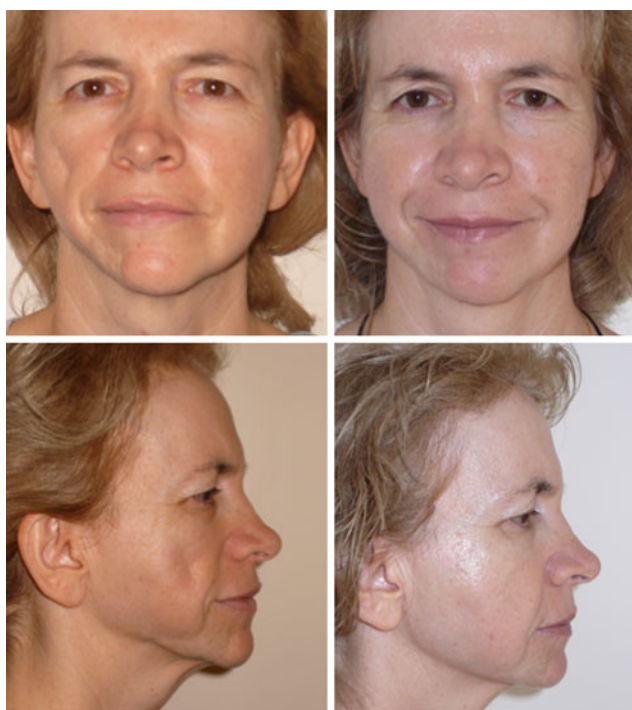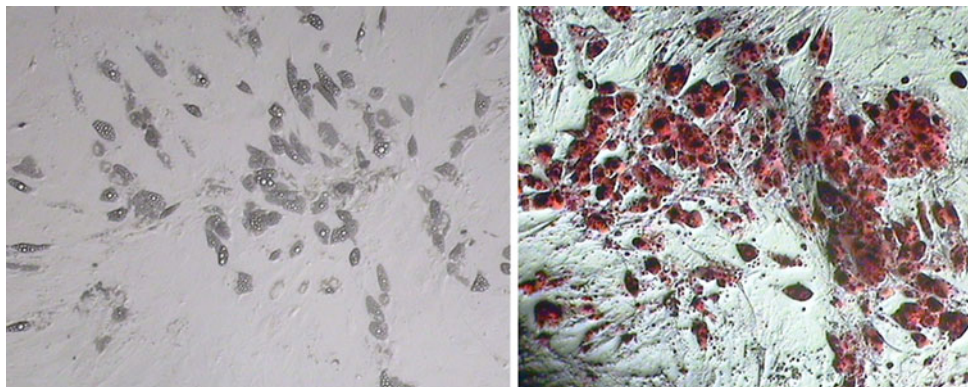
Autologous fat transplantation is an ideal treatment for facial rejuvenation and soft tissue augmentations providing “like for like” tissue material; however, the success of traditional fat grafting has been unpredictable and often unsatisfactory. The lingering clinical confusion associated with the viability and predictability of fat grafting is related to the mechanism of fat survival in the recipient area [10]. For large-volume fat transfers or transfers into a hostile recipient bed, the recipient area vascularity might be insufficient for the ischemic graft, leading to graft necrosis. This may be particularly true for injections into areas where the circulation and wound-healing capacity is impaired by previous fibrosis due to surgery, injections,

radiotherapy, or any other acquired pathology. One recent innovation to deal with such problems is the enrichment of the transplant with autologous regenerative cells [9, 11]. For example, Yoshimura et al. [12] described a cell-assisted lipotransfer (CAL) method to graft large amounts of fat for breast augmentation and breast reconstruction.

Adipose-derived regenerative cells can be obtained from the processing of either liposuctioned or excised fat. Despite its ease of harvest and the volume of tissue obtainable from liposuction, adipose tissue contains 100–1000 times more pluripotent cells per cubic centimeter than bone marrow [13]. According to the literature, it is possible to harvest up to  $200 \times 10^6$  regenerative cells from 500 cc of lipoaspirate, which makes cell culture unnecessary [14]. These regenerative cells contain several types of cells, including adipose-derived stem cells, vessel-forming cells, and progenitor cells, from which a variety of mesodermal cell types (bone, cartilage, blood) can be derived. Although the exact mechanism of ADRCs is unknown, it is thought that ADRCs contribute to graft survival through proangiogenic, antiapoptotic, proadipogenic effects [9]. Indeed, these cells have been shown to promote adipose cell replication, incorporate into vessel walls, and decrease the local inflammatory response [15]. By combining traditional fat grafting with ADRCs, we tried to overcome the problems associated with autologous fat transfer into areas with an impaired environment for fat graft survival. In SET injections, autologous ADRCs are used to promote angiogenesis during the critical time of tissue engraftment, attempting to improve the survival rate of tissue and reduce postoperative volume loss.

Prior to clinical application, the efficiency of manual cell isolation and the immunogenic phenotype of the filtered cell suspension were optimized and characterized as a part of another study (unpublished). Briefly, purification efficiency had been validated by using FITC- or PE-conjugated secondary antibodies that recognize magnetic beads. The rate of fluorescence was then determined by both flow cytometry and fluorescent microscopy. The immunological phenotype of ADRCs in the enriched cell suspension and the level of enrichment had been documented by flow cytometry performed for antibodies CD90, CD45, CD34, CD73, and CD105 before and after magnetic separation (data not shown). Also, as a control study, similar amounts of lipoaspirated material were enzymatically digested and the resulting SVF was magnetically purified, as explained above. Obtained cells were then cultured and induced to *in vitro* adipogenesis, as described elsewhere [16]. Results of “Oil Red O staining” are shown in Fig. 1. These results show that magnetically purified progenitor cells can indeed retain their adipogenic differentiation potential, indicating that they may behave similarly *in vivo* after SET injections.

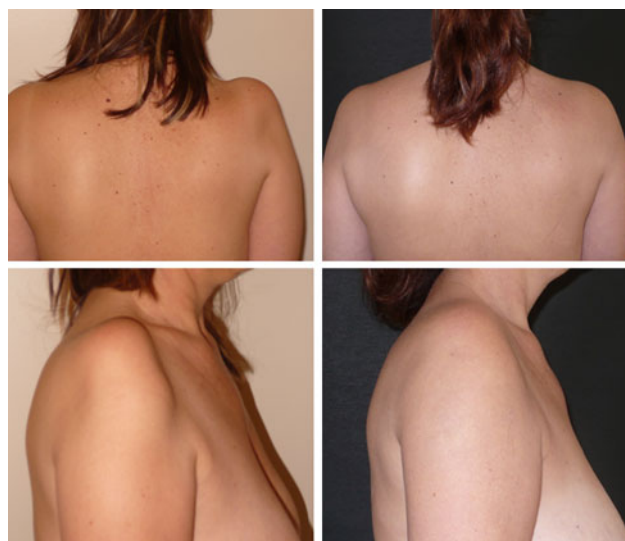**Fig. 1** Results of “Oil Red O staining” have shown that magnetically purified progenitor cells can indeed retain their adipogenic differentiation potential, indicating that they may behave similarly in vivo after SET injections



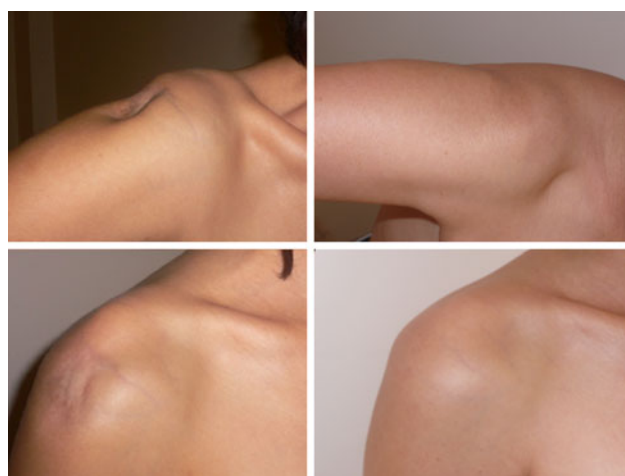**Fig. 2** *Left* Preprocedure photos of Parry Romberg case that had two previous unsuccessful traditional fat transfers. Several years later, a single SET procedure was used to correct the defect, using 42-cc SET injection. *Right* 18 months after SET procedure

In this series the technique was successful, particularly in four secondary cases that had been previously treated with traditional fat grafting without any significant improvement (Fig. 2). Similarly, cases in which typically there is relatively insufficient revascularization due to massive transplantations, such as breast augmentations or large-volume soft tissue reconstructions, may be important indications for SET (Fig. 3). Moreover, the SET injections seem to have a therapeutic effect on the overlying skin (Fig. 4).

It can be speculated that previous attempts of fat transfers might have prepared the recipient bed and for this reason there was better take during subsequent SET



**Fig. 3** *Left* Childhood polio sequel of the right shoulder. *Right* 18 months after single session of 180-cc SET injection



**Fig. 4** *Left* Iatrogenic skin/soft tissue defect due to subcutaneous steroid injection treated with a single session of 8-cc SET injection. Subjective improvement in the skin quality was observed. *Right* 18 months after procedure



injections. However, the outcomes from the SET injections seemed dramatically better than the previous procedure. In particular, two cases in which traditional grafting failed twice before SET injection might be used to show that it is the cells, not the prepped recipient bed, that contributes to the better outcomes.

Although this case series describes injecting ADRCs into an area that had been grafted with non enriched fat just hours before, much of the literature describes combining the ADRCs with the fat graft *ex vivo* and then injecting the cell-enriched graft as a single substance. One advantage of the method described in this series is a reduction in the time the patient is spending in the OR. This, quite obviously, will lead to a reduction in total procedure cost. There are not enough clinical data to favor either of these approaches, but both methods mentioned above include all three of the basic components of tissue engineering: the fat as the transfer scaffold, ADRCs as the therapeutic cellular material, and PRP as growth factors.

Another discussion might be about the ADSC isolation level. In the literature, the use of the SVF is widely discussed. This fraction includes regenerative cells, as well as T cells and B cells, which are very important for the inflammatory response. Using magnetic sorting, we are able to further isolate the regenerative cells from these inflammatory cells. Still, it is not known if this separation is clinically advantageous. However, in a comparative study recently done by our group, it was observed that when the same number of cells were plated (before and after manual cell isolation), the colony-forming efficiency was found to be at least fourfold higher in the magnetically isolated cell suspensions. On the other hand, once the primary cell lines were established, both cell populations gave rise to similar adipogenic, chondrogenic, and osteogenic differentiation rates at passage 4 (data not shown). Therefore, it can be speculated that magnetic purification may exert its positive effect by (1) allowing the operator to be able to inject concentrated ADRCs in a selected area thereby promoting their tissue repair and rejuvenation capabilities, and (2) minimizing operation-dependent inflammatory responses by eliminating residual lymphocytes and immunomodulatory cell populations in the prepared sample.

Future studies should include the use of a control group and more accurate documentation of the volume of fat that is retained. Nonetheless, our data and a growing number of studies in the literature suggest that this new technique may have significant comparative advantages such as superior graft uptake and tissue regeneration. These advantages may be most important in hostile recipient areas such as fibrotic tissues or irradiated areas. It is important to stress that we need further understanding of specific factors that predict the enhanced survival of fat grafting.

Recently, plastic surgery has experienced two revolutions regarding adipose tissue. First, fat has been recognized as the best source of autologous regenerative cells. Second, plastic surgeons have realized that they have easy access to these important cells via a manual laboratory process or an innovative medical device. Given the plastic surgeon's familiarity with adipose tissue, this group may turn out to be the grandfathers of an emerging field of medicine: cell therapy.

## Conclusions

Because of two recent revolutions, namely, the recognition of fat tissue as the most important source of stem cells in the human body and the relatively simple technique of isolating these stem cells from fat, plastic surgeons might emerge as the specific group who will harvest stem cells in abundance without the need of expanding them for weeks in expensive facilities, and provide the other specialties with this never-ending regenerative power.

The preliminary results of our work suggest that regenerative cell-enriched tissue injections may have significant advantages compared to traditional fat transplantation. These ADRCs may mitigate early ischemia by increasing angiogenesis, decreasing apoptosis, and modulating the local inflammatory response. One of the important advantages of the method described in this series is a reduction in the time the patient spends in the OR. This, quite obviously, will lead to a reduction in total procedure cost.

It is clear that further studies are necessary in order to prove a significant advantage of regenerative cell enrichment compared to traditional fat transfer methods. However, to date, our data suggest that SET injections might have some value to the surgeon, particularly when grafting high volumes of fat or when faced with hostile recipient area conditions, including fibrosis and postradiation.

**Disclosure** The authors have no conflicts of interest to disclose.

## References

1. Domergue S, Psomas C, Yachouh J et al (2006) Fat microinfiltration autografting for facial restructuring in HIV patients. *J Craniomaxillofac Surg* 34:484–488
2. Shakhov AA (2002) Fat transplantation and breast augmentation. *Aesthetic Plast Surg* 26:323–325
3. Tzikas TL (2006) Autologous fat grafting for midface rejuvenation. *Facial Plast Surg Clin North Am* 14:229–240
4. Butterwick KJ, Nootheti PK, Hsu JW et al (2007) Autologous fat transfer: an in-depth look at varying concepts and techniques. *Facial Plast Surg Clin North Am* 15:99–111, viii

5. Toledo LS, Mauad R (2006) Fat injection: a 20-year revision. *Clin Plast Surg* 33:47–53, vi
6. Nguyen A, Pasyk KA, Bouvier TN et al (1990) Comparative study of survival of autologous adipose tissue taken and transplanted by different techniques. *Plast Reconstr Surg* 85:378–386
7. Billings E Jr, May JW Jr (1989) Historical review and present status of free fat graft autotransplantation in plastic and reconstructive surgery. *Plast Reconstr Surg* 83:368–381
8. Coleman SR (1997) Facial recontouring with lipostructure. *Clin Plast Surg* 24:347–367
9. Zhu M, Zhou Z, Chen Y et al (2010) Supplementation of fat grafts with adipose-derived regenerative cells (ADRCs) improves long-term graft retention. *Ann Plast Surg* 64(2):222–228
10. Ellenbogen R, Motykie G (2006) Adipose stem cells. *Plast Surg Pract.* [http://www.plasticsurgerypractice.com/issues/articles/2006-12\\_06.asp](http://www.plasticsurgerypractice.com/issues/articles/2006-12_06.asp)
11. Yoshimura A, Aoi N, Kurita M et al (2010) Progenitor-enriched adipose tissue transplantation as rescue for breast implant complications. *Breast J* 16:169–175
12. Yoshimura K, Sato K, Aoi N et al (2008) Cell-assisted lipotransfer for cosmetic breast augmentation: supportive use of adipose-derived stem/stromal cells. *Aesthetic Plast Surg* 32:48–55
13. Strem BM, Hicok KC, Zhu M et al (2005) Multipotential differentiation of adipose tissue-derived stem cells. *Keio J Med* 54:132–141
14. Aust L, Devlin B, Foster SJ, Halvorsen YD, Hicok K, du Laney T, Sen A, Willingmyre GD, Gimble JM (2004) Yield of human adipose-derived adult stem cells from liposuction aspirates. *Cytotherapy* 6:7–14
15. Rehman J, Traktuev D, Li J, Merfeld-Clauss S, Temm-Grove CJ, Bovenkerk JE, Pell CL, Johnstone BH, Considine RV, March KL (2004) Secretion of angiogenic and antiapoptotic factors by human adipose stromal cells. *Circulation* 109:1292–1298
16. Zuk PA, Zhu M, Ashjian P, De Ugarte DA, Huang JI, Mizuno H, Alfonso ZC, Fraser JK, Benhaim P, Hedrick MH (2002) Human adipose tissue is a source of multipotent stem cells. *Mol Biol Cell* 13:4279–4295